Equine Veterinary Education

EQUINE VETERINARY EDUCATION
Equine vet. Educ. (2021) •• (••) ••-••
doi: 10.1111/eve.13533

Review Article

A review of laminitis in the donkey

A. K. Thiemann*, J. Buil, K. Rickards and R. J. Sullivan

The Veterinary Department, The Donkey Sanctuary, Offwell, Honiton, Devon, UK
**Corresponding author email: alex.thiemann@thedonkeysanctuary.org.uk*

Keywords: horse; donkey; laminitis; nutrition; endocrinopathic; farriery

Summary

Laminitis is a commonly occurring, painful condition of the foot that can have a major impact on the welfare of affected donkeys. When faced with a donkey suspected to have laminitis, the approach is broadly similar to that in the horse, however there are certain factors unique to donkeys that this article aims to highlight including: the differences in use, behaviour, anatomy, therapy and management.

Introduction

Laminitis is a commonly occurring, painful condition of the foot that can have a major impact on the welfare of affected donkeys. When faced with a donkey suspected to have laminitis, the approach is broadly similar to that in the horse, however, there are certain factors unique to donkeys that this article aims to highlight including the differences in use, behaviour, anatomy, therapy and management.

In the UK, donkeys are typically kept as pets or companion animals. There are small populations that work as beach donkeys, in equine-assisted therapy, and some private owners will ride/drive donkeys. The majority, however, lead relatively sedentary lives, which is in stark contrast to the situation of many working donkeys across the globe. Despite this dichotomy in existence, the common theme of human neglect presents as a risk factor for the development of laminitis. Such neglect is often not intentional but results from a lack of awareness and education regarding laminitis in donkeys – including correct dietary and endocrinopathic management of obese and geriatric animals. It is easy for an owner to overlook subtle signs of foot pain in a nonridden donkey, and the stoical behaviour of donkeys makes pain detection difficult. A working donkey may be more overtly lame but the human dependence on the animal for their livelihood may mean the donkey continues to work.

Inadequate and inappropriate farriery and the routine measures needed to ensure good hoof care can add to this unintentional neglect.

This review attempts to use evidence-based donkey-specific material, however, in many cases this is lacking and extrapolation from data for horses must be used. We have included unpublished data from clinical records of donkeys at the Donkey Sanctuary where it is relevant. It is readily apparent that there is a need for larger prospective and retrospective studies to assess prognosis and risk factors in the donkey, in a wide variety of populations.

Aetiology

As in the horse, the major aetiological causes of laminitis in donkeys fall into the broad categories of endocrinopathic, sepsis-associated and supporting limb laminitis.

There is limited available donkey-specific data regarding endocrinopathic laminitis. Older donkeys may be at risk of developing endocrinopathic laminitis associated with pituitary pars intermedia dysfunction – PPID (Gehlan et al., 2020). High basal ACTH measurements have been recorded in donkeys with clinical and radiographic evidence of laminitis; additionally, post-mortem examination (the Donkey Sanctuary, unpublished data) has identified histopathological evidence of pituitary adenomas, in some cases alongside the presence of laminitic change.

Obesity is a common presentation in UK donkeys. Despite a lack of published data validating diagnostic tests of equine or asinine metabolic syndrome (AMS), extrapolation of diagnostic algorithms and testing regimes used in horses (Equine Endocrinology Group, 2020) has indicated evidence of insulin dysregulation in donkeys. Elevated resting insulin and elevated insulin after an oral sugar challenge test have been recorded in donkeys at the Donkey Sanctuary. Whilst work pertaining to asinine metabolic syndrome is largely unpublished, the combination of detection of insulin dysregulation, donkeys with general obesity or regional adiposity, clinical presentation of laminitis and difficulty in achieving weight loss are all highly suggestive that asinine metabolic syndrome (AMS) is a genuine concern (**Fig 1**).

Inappropriate nutrition is the leading cause of obesity in the majority of cases. Donkeys are often provided with diets that are suitable for horses but unless energy demands are increased substantially due to heavy work, late pregnancy or lactation, the energy content of the diet will be excessive for maintenance and weight gain will occur. Donkeys have evolved to survive on sparse, fibrous vegetation using a longer gut transit time to extract sufficient energy from a low

Fig 1: Donkey with regional and generalised obesity.

digestible energy diet (Pearson & Merritt, 1991). This means they require a lower dry matter intake compared to horses and have the capacity to digest a more lignin-rich diet. In general terms, this means that the mainstay of the diet should be straw (if dental function is appropriate for a long fibre diet) with restricted access to grass to provide maintenance energy requirements, and a micronutrient balancer to ensure adequate vitamin and mineral levels.

Donkeys are also susceptible to endotoxin-induced laminitis, which the authors have observed in cases of septicaemia associated with acute typhlocolitis and other septic processes. In the absence of specific anatomical and challenge studies, it is assumed that the mechanism of action is similar to that in the horse (Hood et al., 1993).

Supporting limb laminitis is seen in donkeys suffering acute uncontrolled painful lameness in one limb with consequent overloading of the opposing limb. It is important for the clinician to be aware of the risk and whilst there is no evidence for its effectiveness, precautionary foot support may be helpful as well as improving analgesia.

Management changes such as transportation or walking on hard ground may precipitate a bout of acute laminitis on top of an unrecognised chronic laminitis. A detailed examination of the hoof and digital pulses is sensible before travelling a donkey long distances.

Prevalence

In a UK population of donkeys kept under similar management conditions (the Donkey Sanctuary, unpublished data), 4.2% of the population were seen for clinical signs of laminitis in a 12-month period. Forty-six per cent of these cases were diagnosed as acute laminitis (acute bilateral forelimb pain, weight shifting, altered weight distribution, positive response to hoof tester application and bounding digital pulses). The remaining 54% were classed as chronic laminitis based on one or more of the following signs: pain on hoof tester application, chronic hoof capsule changes and/or altered gait with a shortened stride length with increased founder distance, capsular or phalangeal rotation of P3, reduced sole depth and/or remodelling of P3 identified on radiographs. This ratio is comparable to that found in a study of laminitis in horses presented to first opinion practice (Slater et al., 1995). Nine per cent of the acute cases of laminitis had radiographic evidence of pre-existing chronic laminitis. In the same 12-month period, 6% of donkeys seen for laminitis were subjected to euthanasia for humane reasons directly associated with laminitis and the average age at death was 22 ± 4 years (mean $\pm$ SD). In contrast, the average age of donkeys seen for laminitis was 17 ± 6 years (mean $\pm$ SD). In addition, a further 14% of the donkeys seen for laminitis were subjected to euthanasia due to multiple disease processes (osteoarthritis, dental disease, condition requiring surgery under GA) of which laminitis was a contributory factor in the decision.

Cox et al., (2010) found that 4% of donkeys living in homes in the UK were reported by their owners to have suffered from laminitis during a 12-month period.

Whilst there are studies looking at lameness in working donkeys, no detail is given as to the prevalence of laminitis. In many populations of working donkeys, the combination of workload and lack of access to large quantities of high energy, carbohydrate-rich feeds are likely to reduce the risk of endocrine-associated laminitis, but increase the risk of overload and concussive trauma.

There is currently no objective data on the prevalence of laminitis in donkeys kept for production of meat, milk and skins, however, welfare assessments carried out on farms keeping donkeys for production highlighted that 15% of the animals assessed had signs of hoof neglect although only 2% were lame at the time of assessment (Dai et al., 2016).

Comparative hoof anatomy and laminitis pathology

The external hoof morphology differs between donkeys and horses with the donkey characterised by the presence of an 'upright boxy' hoof compared with the 'inclined rounded' capsule of the horse. Collins et al., (2002) suggested that the donkey hoof capsule could be considered a truncated cylinder whereas the hoof capsule of the horse resembles a truncated cone. The solar surface of the donkey hoof has a distinctive oval shape compared with the horse and generally has a dorsal hoof wall that is 5 to 10 degrees more upright. In the healthy donkey foot, the frog is well-developed, especially at the palmar aspect, but the apex does not extend so far rostral under the pedal bone (**Fig 2a,b**). It is for this reason that heart bar shoes are not considered appropriate for donkeys when support for the pedal bone is required (Thiemann & Poore, 2019). The hoof wall of the donkey is also characterised by the presence of a marked flare at the heels. These characteristics differ from the circular solar profile, tapering heel, and inclined heel angle of the horse hoof. The internal structure of the horn in the donkey hoof is also different resulting in a higher moisture content (Hopegood et al., 2004), which is a beneficial adaptation to the arid environment that donkeys originate from. The functional consequences of the differences in anatomical and ultrastructural properties are poorly defined, however they are likely to influence both the mechanical proprieties of the hoof and the development of foot pathology particularly when donkeys are kept in wetter, temperate climates.

The mechanisms involved in the pathogenesis of laminitis in the horse have not been completely elucidated and are most likely numerous and interrelated (Patterson-Kane et al., 2018). Similar mechanisms are assumed to occur in donkeys however, to the authors' knowledge, no studies have been performed in donkeys to confirm this.

The concept of acute and chronic laminitis has different interpretations; the authors consider acute laminitis to be those cases where there are clinical signs such as recumbency, painful reaction to hoof testers, shortened stride, increased digital pulses, weight shifting and altered weight distribution. Chronic laminitis develops as a result of sufficient lamellar damage to destabilise the pedal bone leading to changes that can be seen on radiographs including rotation (capsular or phalangeal), an increased founder distance (D), which is the distance between the coronary band and the extensor process of the pedal bone and pedal bone remodelling (Collins et al., 2011). These changes may or may not be associated with reduced sole depth (**Figs 3**, **4** and **5**).

There are also changes to the external hoof capsule including divergent rings, stretched white line and flat or convex soles. In horses, depression at the coronary band with finger pressure is indicative of founder, however, as P3 sits

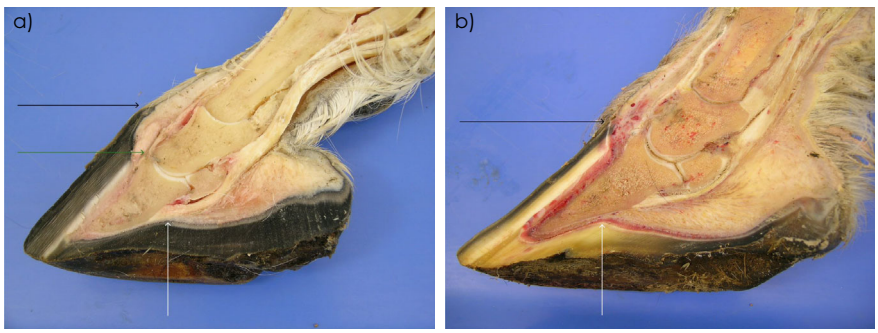

Fig 2: a) Split section of donkey hoof, showing normal distance between top of extensor process and coronary band, and typical location of frog. Black horizontal upper arrow at coronary band, green horizontal lower arrow at extensor process of P3, white vertical arrow at tip of frog. b) Split section of horse hoof to compare with donkey. Note the alignment of the coronary band and the extensor process of P3 (black horizontal arrow) and the forward tip of the point of from (white vertical arrow).

Fig 3: External appearance of laminitic hoof – arrow to note divergent growth rings evident at hoof wall.

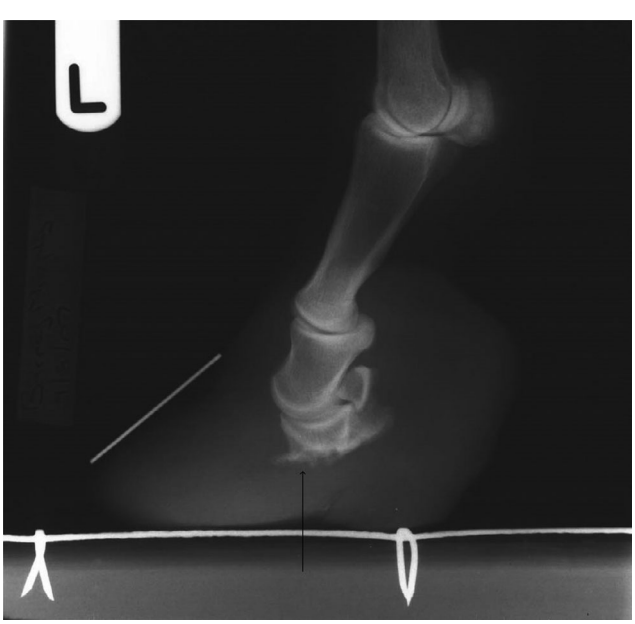

Fig 4: Lateral radiograph of hoof in Figure 3 showing severe chronic laminitic changes, arrow pointing to severely remodelled P3.

more distally in the hoof capsule in donkeys, this technique is difficult to interpret. If there is pain associated with depression at the dorsal coronary band, this should be considered abnormal and warrants further investigation.

Animals with chronic laminitis can suffer from acute episodes and in these cases the donkey will exhibit the clinical signs described above. These acute episodes are often associated with the presence of concomitant laminitis risk factors and are likely to follow a subclinical phase when clinical signs are not detectable but pathology is occurring within the hoof.

Diagnosis

The diagnosis of laminitis in the donkey relies on a number of methods including behavioural observations and pain scoring, clinical signs, blood tests and radiography.

Behavioural observations

The stoical behaviour of the donkey, combined with its light or absent workload often leads to a delayed recognition of laminitis in this species. Donkeys with chronically neglected and overgrown hooves are regularly presented to vets and farriers and are indicators of severely compromised welfare. The natural behaviours of a donkey differ from those of a horse, they have a stronger freeze and fight response in the event of danger and a subtler set of pain responses as evolutionary predator avoidance strategies (Haines & Goliszek, 2019). This combination results in painful donkeys labelled inappropriately as stubborn or dangerous.

Clinical signs

Acute cases of laminitis will present with a number of clinical signs as described above. Hoof testing can be unrewarding in donkeys with thick soles or if using large equine hoof testers. There may also be other signs depending on the inciting cause of the laminitis and a full clinical examination is required to detect underlying disease processes. Any donkey in acute pain can show a reduction in appetite and be at risk of developing hyperlipaemia; blood sampling may be required to monitor for this complication.

Pain scoring

Composite and facial pain scores have been developed for the donkey and when regularly used can be effective at

Fig 5: Split section of hoof in Figure 3 showing severe pathology within hoof capsule.

detection of acute pain and monitoring response to therapy (Van Dierendonck et al., 2020). The composite pain score is most useful for assessing orthopaedic pain and is used regularly in the authors' clinic to monitor progress and response to therapy.

The gait changes in a laminitic donkey are often mild and better described using the 'modified Obel' method as published recently for ponies (Meier et al., 2019). This scale recognises that in many cases early laminitis signs (Obel grade 1 and 2) are better distinguished using subtler descriptors at rest and walk as these animals should not be made to trot to demonstrate lameness. Descriptors include weight shifting, ability to lift a limb, mild/moderate or severe gait stiffness in walk and circling, strength of digital pulse, lying down and abnormal posture. Wherever possible the assessment should be carried out on hardstanding, as this will increase the clinician's ability to identify more subtle signs.

Chronic cases of laminitis are seen frequently and result in changes in the external and internal hoof structure, forelimb musculature and a 'pottery or stilted' gait. Owners may report that the donkey is moving less than they used to but there is the risk that this sign may be overlooked and assumed to be part of a natural ageing process in geriatric donkeys. The external hoof develops characteristic abnormal growth patterns and, in many cases, secondary white line disease develops as stretched laminae allow mixed infections to take hold and white line abscesses are common sequelae. In chronic cases, the sole may become abnormally thin, flat or convex and sensitive to pressure. If laminitis has been combined with hoof neglect and chronically overlong toes, there may be breakdown of the flexor and suspensory apparatus. In severe cases, muscle wastage develops particularly in the shoulder region. Unfortunately, severe changes are seen frequently in geriatric donkeys particularly when changes occur gradually over time and a reduced quality of life is not recognised (Thiemann et al., 2018).

Laboratory testing

There is limited available donkey-specific data regarding endocrinopathic laminitis. Whilst the causal relationship between PPID and laminitis is unclear, testing for PPID should be considered in any donkey with laminitis that is not attributable to a mechanical or inflammatory cause, particularly if there are concurrent clinical signs of muscle loss and depressed demeanour. In the authors' experience, donkeys do not always present with the traditionally characteristic signs of PPID seen in horses, including polydipsia/polyuria. Mendoza et al. (2019a) do mention hypertrichosis as a presenting sign in donkeys with PPID. The donkey's typically long, thick coat and more subtle behavioural repertoire may make PPID signs less obvious so clinicians are urged to consider the whole picture and test for PPID if there is any suspicion. Owners may assume that a donkey's sedentary behaviour is related to character or old age but if mobility has declined, PPID associated laminitis should be on the list of differentials.

Currently, as with horses, measurement of basal ACTH is the initial test of choice. Fluctuations in basal ACTH have been recorded in the same individual, and the effects of various management and animal factors on ACTH in donkeys have not been fully documented. Current recommendations are to measure ACTH at a time when the donkey is not actively stressed, undergoing an active bout of laminitis or has recently undergone significant management changes. Donkey-specific reference ranges for ACTH should be used. Donkey-specific reference ranges for ACTH and basal insulin have been developed by the Donkey Sanctuary (Evans & Crane, 2018) (**Table 1**).

Use of the TRH stimulation test for diagnosis of PPID in donkeys has been described (Mejia-Pereira et al., 2018) but further studies providing donkey-specific reference ranges are lacking. If a diagnosis of PPID is made and medical management is required, then pergolide can be given. Pergolide dosing should follow the same guidelines as for horses; clients must be made aware that this is off licence use. In our experience, the risk of anorexia is quite apparent in donkeys receiving pergolide, usually at the start of therapy but has also been noticed in donkeys who have been on pergolide for some time. As such, clinicians should err on the side of caution when selecting a starting dose and counsel owners to be extra vigilant for any changes in behaviour or appetite that may signal hyperlipaemia.

In horses, hyperinsulinaemia has been associated with PPID cases that have not presented with classical EMS signs. As such, it appears justifiable to recommend that any donkey diagnosed with PPID and a history of laminitis should also be tested for insulin dysregulation, regardless of whether obese or not. If a high resting insulin value has been identified, this is indicative of insulin dysregulation, otherwise a dynamic test should be used.

The testing protocol used at the Donkey Sanctuary follows that in horses (Equine Endocrinopathy Group, 2020), whereby

TABLE 1: Endocrine table

Parameter	Reference range
Insulin	0–15.1 uIU/mL
ACTH (November to June)	2.7–30.4 pg/mL
ACTH (July to October)	9.0–49.1 pg/mL

Donkey-specific reference ranges for ACTH and basal insulin have been developed by the Donkey Sanctuary (Evans & Crane, 2018), validated for adult donkeys aged 3–20 years of age, using the TOSOH AIA-360 analyser.

0.45ml/kg bwt of corn syrup is administered orally (karo-light test), by the donkey's handler and a blood sample taken to measure insulin 75 min later. If practical, basal insulin and blood glucose are measured prior to corn syrup administration. Starvation of donkeys prior to testing is not recommended due to concerns over hyperlipaemia and is unnecessary in the majority of cases, which will be on predominantly straw-based forage diets. If donkeys are receiving higher energy feeds additional to their forage source, for any reason, supplementary feeds should not be given for 12 h prior to testing. Where donkeys are needle shy a single insulin measurement, post corn syrup is appropriate. In the absence of donkey-specific data for the karo-light test, results should be interpreted in line with those reference ranges for horses and taking due consideration of concurrent clinical signs.

Adiponectin tests have become available in the UK for horses, however, as yet, such tests have not been validated in donkeys, to the best of the authors' knowledge and do not offer additional diagnostic information.

Radiography

A lateromedial radiograph is the most useful view of the pedal bone to assess founder distance, solar depth and rotation within the hoof. In addition, an upright dorsopalmar view will help in the assessment of the palmar process and the associated remodelling and demineralisation. The dorsopalmar weight-bearing view will be the best approach to assess lateromedial imbalances (Balch et al., 1995). One of the most clinically important radiographic differences is that the mean founder distance (D) in normal donkeys is 10.4 mm, compared to 3–5 mm in horses (Collins et al., 2011). The mean hoof wall depth is also 25% greater in donkeys than in ponies. Collins et al., (2011) also confirmed the near parallel alignment between the dorsal aspect of the hoof wall and dorsal aspect of the pedal bone in healthy donkey hooves and stated that donkeys can develop distal displacement of the pedal bone before rotation in a laminitic crisis. Radiographic findings of $D > 13$ mm is indicative of distal displacement (Collins et al., 2011). In a previous study, Walker et al., (1995) concluded that rotation of the distal phalanx occurs in some, but not all laminitic donkeys. Normal sole depth has not been established in donkeys and it could depend on size or breed, however, the authors consider that a sole depth < 10mm is indicative of thin soles and soles ≤ 5mm are classified as severely thin in European donkeys.

It should also be noted that the severity of pathological change identified on diagnostic radiographs may not reflect the true extent of the disease process. Sefton (2019) found an increased degree of pedal bone rotation when comparing this measurement on radiographs taken diagnostically and at post mortem, which may have relevance when assessing donkeys or post mortem specimens as part of a legal/welfare investigation.

Whilst the initial radiographic findings in cases of chronic laminitis include displacement of the pedal bone with or without a reduction in sole depth, the resultant chronic trauma to the pedal bone can lead to demineralisation predominantly at the toe resulting in remodelling of the bone in this region. Initially, this results in a concavity at the dorsal surface of the bone, which develops into a curling up of the distal tip (Turkish slipper appearance) and in the most severe cases a blunting of the tip with the bone shape becoming severely distorted (**Fig 4**). These changes also affect the hoof capsule causing abnormal horn tubule growth resulting in a markedly stretched white line, which is then predisposed to white line abscesses. They also result in further instability of the pedal bone causing ongoing pain.

Digital venography is not routinely used to monitor the development/progression of laminitis in donkeys, however, vascular compromise occurs days or weeks before displacement of the distal phalanx (D'Arpe & Bernardini, 2010) so this technique could be a valuable diagnostic tool to enable early intervention such as box rest and mechanical support. Digital venograms are used to obtain information about veins which are compressed by dislocated soft and/or osseous tissues (Eastman et al. 2012). Retrograde venography in the digit has been described in donkeys (Nocera et al., 2020) which demonstrated abnormalities to blood flow in subclinical cases of laminitis compared to healthy feet.

Prognosis

In view of the stoic nature of donkeys, early signs of laminitis may go unnoticed and it is not uncommon to find radiographic changes indicative of chronic laminitis with no history of the condition having been seen by the owner. It is therefore important to provide good owner education both about the signs to be aware of and the risk factors. Once remodelling has occurred to the extent that overall bone shape has changed, the prognosis is poor and when examined carefully on a suitable surface signs such as weight shifting and bilateral shortened stride length become apparent. In the authors' experience, these cases often cannot be kept comfortable and euthanasia is required.

Therapy

A treatment plan should encompass the management changes, physical and psychological health, pharmacological interventions and remedial farriery required.

Any donkey that needs box rest should have its bonded companion close by or rested with it to avoid stress (**Fig 6**). A deep, nonedible bedding provides comfort when recumbent, (shavings are preferable to cardboard/straw, which donkeys may eat in significant quantities resulting in impaction colic). Appetite and faecal output should be monitored closely as a reduction in either can accompany hyperlipaemia and colic (Burden et al., 2011). Many donkeys are unused to being stabled, but boredom and stress can be minimised by the use of environmental enrichment (Donkey Sanctuary, 2020).

Analgesia for donkeys requires careful monitoring of their behaviour and pain score. Multimodal therapy is most effective using a combination of NSAIDs, paracetamol, and opioids. In most cases these drugs will be used off licence so require informed consent. Many NSAIDs have faster clearance times in donkeys so it is usual to give phenylbutazone at a loading dose of 4.4 mg/kg twice daily followed by a maintenance dose of 2.2 mg/kg twice daily. Flunixin meglumine may be useful in endotoxin-associated laminitis. Meloxicam, ketoprofen and firocoxib are also reported to need significantly more frequent dosing (Mendoza et al., 2019b) so are less preferable. Paracetamol at 20 mg/kg bwt twice daily orally is a useful economical adjunct treatment. Low doses of anxiolytic medication such

Fig 6: Donkey being box rested with companion present to alleviate stress.

as acetylpromazine may encourage a donkey to rest. Of the other available analgesics, including opioids, ketamine, tramadol and gabapentin there is a lack of research available to modify standard doses used in equines. Our approach is to start at an equine dose and use regular pain scoring to assess response to treatment.

Digital hypothermia is the only therapeutic intervention proven to dramatically reduce the severity of sepsis-related laminitis in experimental studies and lower the incidence of laminitis in clinical cases of colitis in horses (van Eps & Pollitt, 2004; Kullmann et al., 2014). Cryotherapy reduces digital pulses and lameness resulting in a lower pain score and minimises lamellar damage. In the authors' experience, this technique is a useful tool in donkeys if applied at the onset of acute laminitis. The hoof wall and pastern should be immersed in ice and water aiming to keep the hoof wall surface temperature at 7–10°C for 48 h (**Fig 7**).

The goal of initial therapy when treating the biomechanical effects of acute laminitis is to minimise the lamellar injury and prevent any displacement. As described by Mitchell et al., (2014) in their review of equine acute laminitis, it is unclear whether the stress from weight bearing, the tension on the deep digital flexor tendon, or a combination of these forces leads to failure of the lamellar attachments in horses that subsequently develop displacement of the pedal bone. Mechanical support to the hoof has two goals in mind: limiting displacement of the pedal bone and increasing patient comfort.

Orthopaedic management during acute laminitis aims to support the feet in order to: (1) reduce stress on the dorsal hoof wall, (2) reduce pressure on the sensitive area of the sole immediately below the dorsal margin of the distal phalanx and (3) in some cases to decrease the tension exerted by the deep digital flexor tendon (O'Grady 2010).

Recruiting the palmar structures of the hoof, including the frog, into the weight bearing surface will reduce stress on the dorsal hoof wall. Additional support over the frog using impression materials and cotton bandages can be useful in horses to provide comfort during the acute stage (Sleutjens et al., 2018). Due to the different anatomic relationship between the frog and the pedal bone within the donkey digit, the authors provide additional support over the solar surface rather than specifically to the frog.

Fig 7: Icing the distal limbs can be a useful tool in the management of laminitis.

Laminitis is considered chronic once the distal phalanx has displaced within the hoof capsule (Hood, 1999). There are three manifestations of displacement of the distal phalanx: dorsal rotation (capsular or phalangeal), distal displacement (sinking), and medio-lateral rotation or asymmetric distal displacement. A combination of all three forms of displacement can exist simultaneously (O'Grady 2010) and in the authors' experience both capsular and phalangeal rotation can occur. Orthopaedic management of chronic laminitis is controversial and multiple trimming and shoeing techniques have been attempted in horses and donkeys with variable success, probably dependent on individual case factors. The main orthopaedic goals should be to maintain comfort, avoid further structural damage and promote repair.

Corrective farriery for chronic laminitis should aim to (1) recruit all available ground surface that is capable of bearing weight, (2) position break over appropriately, and (3) provide heel elevation, if necessary (O'Grady, 2009). Trimming the dorsal hoof wall to restore a parallel relationship between the wall and the dorsal surface of the pedal bone is important to achieve an adequate break over and avoid excessive forces being exerted on the dorsal lamellae. Different techniques can be used to achieve this but it is important not to overexpose the inner lamellae. Heart bar shoes need careful consideration and accurate placement as the apex of the frog does not extend as rostral as in horses meaning they could perpetuate the rotational forces exerted on the pedal bone (Thiemann & Poore, 2019).

Overgrowth of the heels should be corrected gradually as aggressive trimming back to a normal position can produce tension on the DDFT, potentially inducing or exacerbating pedal bone rotation. Many donkeys naturally have a broken forward hoof pastern axis, which the clinician and farrier

Fig 8: An acrylic rim shoe applied to a donkey hoof, supportive gel inserts can be used to protect the sole as well (not shown).

need to carefully assess to avoid increasing the force that the deep digital flexor tendon exerts on the pedal bone and the resultant risk of further displacement.

Acrylic materials or iron shoes are useful in the chronic stage to protect the sole and provide additional comfort. The frog should ideally contact the ground. In the experience of the authors, fast hardening gel materials in combination with an acrylic shoe have proved to be useful to give additional support to the sole, frog, pedal bone and DDFT to prevent further pedal bone displacement and increase comfort (**Fig** 8).

Dietary management

One of the most common causes of laminitis in donkeys is excessive dietary carbohydrate with or without underlying metabolic disease, often secondary to obesity.

Obesity is a common problem in UK donkeys and in a recent study, 27% of donkeys being relinquished to the Donkey Sanctuary were assessed as overweight or obese (Barrio et al., 2021).

Donkeys are usually assessed using a five-point body condition scoring (BCS) system (Donkey Sanctuary, 2018) and learning how to do this and regularly monitoring BCS is a useful preventative tool for vets and owners.

Dietary adjustment forms an important part of any treatment and prevention plan. Donkeys have a daily dry matter intake (DMI) of between 1.3–1.8% of bodyweight and for maintenance have a digestible energy (DE) requirement of 88–117 kJ DE/kg in summer and winter, respectively (Burden & Bell, 2019). In practical terms, this means that a standard sized UK donkey weighing around 180 kg can be given 2.5–3.5kg of good quality barley straw over a 24-h period (assuming a DE content of the barley straw of 5.5–6.5 MJ/kg). This will satisfy appetite without providing excess DE. This should be supplemented with a low energy balancer to provide micronutrients, which are essential for good quality horn production.

Any dietary modification should be introduced gradually to avoid colic and/or colitis and as mentioned previously a thorough dental examination should be performed, particularly if regular dental treatment has not been provided and/or the donkey is not used to a straw only diet. Once the donkey is comfortable and is able to move around again, grazing management should be reviewed to avoid excessive ingestion of fructans associated either with lush, single species grass lays such as rye grass or stressed tightly grazed land or frost-damaged grass.

Ideally, donkeys should graze mixed species grass lays with exposure to hedgerows for browsing. For donkeys that need to lose weight, this should be done gradually with the aim of a reduction of no more than 5% of bodyweight per month, as rapid weight loss is another risk factor for hyperlipaemia (Evans & Crane, 2018). This can be achieved in most cases by reducing the calorific content of the diet rather than limiting quantity to below the maintenance DMI.

Summary

This article has provided the clinician with donkey-specific information to assist them in their approach to a case of laminitis. It is important to note that achieving a successful outcome requires the combined efforts of the clinician, owner and their farrier; and all need to be aware of the important differences that donkeys with laminitis exhibit so they can adjust their approach accordingly. With a correct, prompt diagnosis, an appropriate treatment and long-term management plan, donkeys with laminitis can respond well. In those cases where this has not occurred and particularly if there are obvious changes to the external hoof capsule, it is advisable to take radiographs sooner rather than later to assess the degree of bony change that has occurred, as this can be significant and an important factor when reviewing quality of life.

Authors' declarations of interest

No conflicts of interest have been declared.

Ethical animal research

Not applicable to this review article.

Source of funding

No funding received.

Authorship

All listed authors have participated in the writing of sections and collection of images. A. Thiemann is responsible for the final editing and submission of the manuscript.

References

Balch, O., Butler, D., White, K. and Metcalf, S. (1995) Hoof balance and lameness: improper toe length, hoof angle, and mediolateral balance. *Compendium on Continuing Education for the Practicing Veterinarian* **10**(**17**), 1275–1283.

Barrio, E.B., Giral, I.D.B., Thiemann, A.K. and Varingos, F.J.V. (2021) Demography, Preventative health care and reasons for relinquishment of donkeys to an equine charity in the UK (2013–2015). *Equine Veterinary Journal* **53**(**2**), 324–330.

Burden, F.A. and Bell, N. (2019) Nutrition and Malnutrition of donkeys. *Veterinary Clinics of North America: Equine Practice* **35**(**3**), 469–479.

Burden, F.A., Du Toit, N., Hazell-Smith, E. and Trawford, A.F. (2011) Hyperlipaemia in a population of aged donkeys: description,

prevalence, and potential risk factors. *Journal of Veterinary Internal Medicine* **25**(**6**), 1420–1425.

Collins, S.N., Dyson, S.J., Murray, R.C., Burden, F. and Trawford, A. (2011) Radiological anatomy of the donkey's foot: objective characterisation of the normal and laminitic donkey foot. *Equine Veterinary Journal* **43**(**4**), 478–486.

Collins, S.N., Wealleans, H., Hopegood, L., Latham, R.J., Newlyn, H.A. and Reilly, J.D. (2002) *Current studies on the donkey hoof. Medicine and Surgery of the Donkey*. In: Proceedings 2nd CPD Course Glasgow, UK. pp 1–15.

Cox, R., Burden, F., Proudman, C.J., Trawford, A.F. and Pinchbeck, G.L. (2010) Demographics, management and health of donkeys in the UK. *The Veterinary Record* **166**(**18**), 552–556.

Dai, F., Dalla, C.E., Murray, L.M., Canali, E. and Minero, M. (2016) Welfare conditions of donkeys in Europe: initial outcomes from on-farm assessment. *Animals* **6**(**1**), 5.

D'Arpe, L. and Bernardini, D. (2010) Digital venography in horses and its clinical application in Europe. *The Veterinary Clinics of North America. Equine Practice* **26**(**2**), 339–359.

Donkey Sanctuary (2020) Environment Enrichment: The Donkey Sanctuary's Guide to Enriching the Lives of Donkeys and Mules. Available at: https://view.pagetiger.com/EnvironmentalEnrichmentforDonkeys/EnvironmentEnrichmentfordonkeys. Accessed October 19, 2020

Eastman S., Redden R. F., Williams C. A. (2012) 'Venograms for use in laminitis treatment'. *J. Equine Vet. Sci.*, **11**(**32**): 755–759.

van Eps, A.W. and Pollitt, C.C. (2004) Equine laminitis: cryotherapy reduces the severity of the acute lesion. *Equine Veterinary Journal* **36**(**3**), 255–260.

Equine Endocrinology Group (2020) Recommendations for the Diagnosis and Management of Equine Metabolic Syndrome (EMS). Available at https://sites.tufts.edu/equineendogroup/files/2020/09/200592_EMS_Recommendations_Bro-FINAL.pdf (Accessed 9 Nov 2020).

Evans, L. and Crane, M. (Eds.) (2018) Hyperlipaemia and the Endocrine System. In: *Clinical Companion of the Donkey*. 1st edition, Leicestershire: Troubador Publishing Ltd, p 88.

Gehlan, H., Schwarz, B., Bartmann, C., Gernhardt, J. and Stöckle, S.D. (2020) Pituitary Pars Intermedia Dysfunction and Metabolic Syndrome in Donkeys. *Animals* **10, 2335**, doi:10.3390/ani10122335.

Haines, A. and Goliszek, J. (2019) Donkey and mule behaviour for the veterinary team. *UK-Vet Equine* **3**(**1**), 27–32.

Hood, D.M. (1999) Laminitis in the horse. *Veterinary Clinics of North America: Equine Practice* **15**(**2**), 287–294.

Hood, D.M., Grosenbaugh, D.A., Mostafa, M.B., Morgan, S.J. and Thomas, B.C. (1993) The role of vascular mechanisms in the development of acute equine laminitis. *Journal of Veterinary Internal Medicine* **7**(**4**), 228–234.

Hopegood, L., Collins, S.N., Latham, R.J. and Reilly, J.D. (2004) Analyses of the moisture content of hoof horn from horses, donkeys and laminitic donkeys. *BSAP Occasional Publication* **32**, 169–171.

Kullmann, A., Holcombe, S.J., Hurcombe, S.D., Roessner, H.A., Hauptman, J.G., Geor, R.J. and et al. (2014) Prophylactic digital cryotherapy is associated with decreased incidence of laminitis in horses diagnosed with colitis. *Equine Veterinary Journal* **46**(**5**), 554–559.

Meier, A., de Laat, M., Pollitt, C., Walsh, D., McGree, J., Reiche, D.B. et al. (2019) A "modified Obel" method for the severity scoring of (endocrinopathic) equine laminitis. *Peer J.* **7**, e7084.

Mejia-Pereira, S., Perez-Ecija, A., Buchanan, B.R., Toribio, R.E. and Mendoza, F.J. (2018) Evaluation of dynamic testing for pituitary pars intermedia dysfunction diagnosis in donkeys. *Equine Veterinary Journal* **51**(**4**), 481–488.

Mendoza, F.J., Perez-Ecija, A. and Toribio, R.E. (2019b) Clinical pharmacology in donkeys and mules. *The Veterinary Clinics of North America. Equine Practice* **35**(**3**), 589–606.

Mendoza, F.J., Toribio, R.E. and Perez-Ecija, A. (2019a) Metabolic and endocrine disorders in donkeys. *The Veterinary Clinics of North America. Equine Practice* **35**(**3**), 399–417.

Mitchell, C.F., Fugler, L.A. and Eades, S.C. (2014) The management of equine acute laminitis. *Veterinarni Medicina* **22**(**6**), 39–47.

Nocera, I., Aliboni, B., Ben David, L., Gracia-Calvo, L.A., Sgorbini, M. and Citi, S. (2020) Radiographic and venographic appearance of healthy and laminitic feet in amiata donkeys. *Frontiers in Veterinary Science* **7**. https://doi.org/10.3389/fvets.2020.601665.

O'Grady, S.E. (2009) Guidelines for trimming the equine foot: a review. *Proceedings of American Association of Equine Practitioners.* **55**, 218–225.

O'Grady S. E. (2010) 'Farriery for Chronic Laminitis'. *Vet Clin North Am Equine Pract*, **26**(**2**): 407–423.

Patterson-Kane, J.C., Karikoski, N.P. and McGowan, C.M. (2018) Paradigm shifts in understanding equine laminitis. *The Veterinary Journal* **231**, 33–40.

Pearson, R.A. and Merritt, J.B. (1991) Intake, digestion and gastrointestinal transit time in resting donkeys and ponies and exercised donkeys given ad libitum hay and straw diets. *Equine Veterinary Journal* **23**(**5**), 339–343.

Sanctuary, D.. (2018) Donkey Body Condition Score Chart. https://www.thedonkeysanctuary.org.uk/sites/uk/files/2018-10/body-scoring-chart.pdf, accessed 10/3/21

Sefton, A. (2019) Laminitis in donkeys: a pilot study investigating radiographic versus post mortem measurements. *Equine Veterinary Journal* **51**(**S53**), 10.

Slater, M.R., Hood, D.M. and Carter, G.K. (1995) Descriptive epidemiological study of equine laminitis. *Equine Veterinary Journal* **27**(**5**), 364–367.

Sleutjens, J., Serra Bragança, F.M., van Empelen, M.W., Ten Have, R.E., de Zwaan, J., Roelfsema, E. et al. (2018) Mouldable, thermoplastic, glue-on frog-supportive shoes change hoof kinetics in normal and obese Shetland ponies. *Equine Veterinary Journal* **50**(**5**), 684–689.

Thiemann, A.K., Barrio, E., Rickards, K. and Harrison, A. (2018) Assessing quality of life and welfare of donkeys in the UK. *In Practice* **40**, 249–257.

Thiemann, A.K. and Poore, L.A. (2019) Hoof disorders and farriery in the donkey. *The Veterinary Clinics of North America. Equine Practice* **35**(**3**), 643–658.

Van Dierendonck, M.C., Burden, F.A., Rickards, K. and van Loon, J.P.A.M. (2020) Monitoring acute pain in donkeys with the equine utrecht university scale for donkeys composite pain (EQUUS-DONKEY-COMPASS) and the Equine Utrecht University Scale for Donkey Facial Assessment of Pain (EQUUS-DONKEY-FAP). *Animals* **10**(**2**), 354.

Walker, M., Taylor, T., Slater, M., Hood, D., Weir, V. and Elslander, J. (1995) Radiographic appearance of the feet of mammoth donkeys and the finding of subclinical laminitis. *Veterinary Radiology & Ultrasound* **36**, 32–37.